

Protecting the root

Prof. Dr. Liviu Steier outlines how best to prevent gingival recession

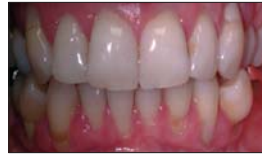Root surface exposure as a consequence of gingival recession is a challenge for the dental practitioner. Over the past decade, many procedures have been introduced and presented to prevent and/or treated this complex phenomenon. Most of the treatment approaches consist of mucogingival graft techniques.

Variation in gingival thickness (GTH) has been related to different periodontal 'biotypes' (Seibert & Lindhe 1989):

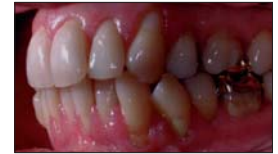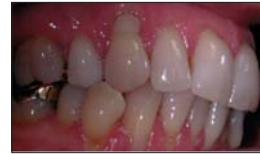- Thick – flat biotype (quadratic teeth with a broad zone of keratinised tissue)
- Thin – scalloped biotype (slender teeth with a narrow zone of keratinised tissue)

Gingival thickness not only interferes with dental procedures but can advance if left untreated. Among the most common found clinical manifestations are:

- Tooth sensitivity.
- Long tooth appearance



A clinical case of generalised gingival recession in a patient with thin gingiva biotype and high muscular insertion.



Gingival biotype and natural teeth

As a consequence of this thin biotype, gingiva can recede during life. It is not often that clinical situations like the one below can be seen in practice. Treatment which doesn't address the primary disease was performed using adhesive filling material to reduce tooth sensitivity and mask esthetics. With time, restorations have to grow and an unpleasant image occurs.

Gingival biotype and prosthetics

Ericsson & Lindhe demonstrated in an experimental study (1984) performed on beagle dogs, that once metallic strips were inserted subgingivally, recession was more likely to appear in areas with thin gingiva architecture.

Gingival biotype and surgical endodontics

It is a widely accepted clinical impression that a thin, highly-

scalloped gingiva tends to recede from source of irritation, for example, an artificial crown. Margin or microbial irritants (Seibert & Lindhe 1989), and gingival recession often occurs following traumatic, or surgical injury (Claffey & Shanley 1986).

Gingival biotype and implant therapy in the esthetic zone

(ITI Treatment Guide Vol I – Implant Therapy in the Esthetic Zone – Quintessence 2007)

Subgingival elements covered by a thick – gingival biotype assure a predictable esthetical outcome lowering the treatment risks.

A medium – gingival thickness biotype is associated with higher long-term esthetical risk.

The thin – gingival thickness biotype is associated with the risk of recession and may lead to esthetical insufficiency.

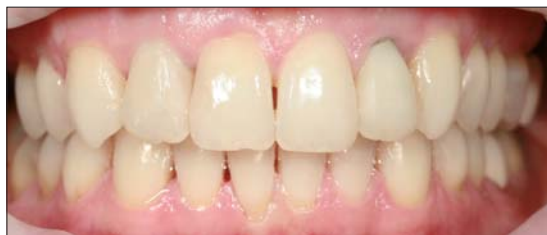Müller et al. (2007) demonstrated that subjects with a thin periodontal phenotype have also relatively thin palatal mucosa not very suitable for harvesting connective tissue grafts. As a consequence, the use of 'acellular dermal matrix' derived from donated human skin (AlloDerm – BioHorizons) may be the only treatment alternative in cases of thin gingiva biotype.

Soft-tissue grafting

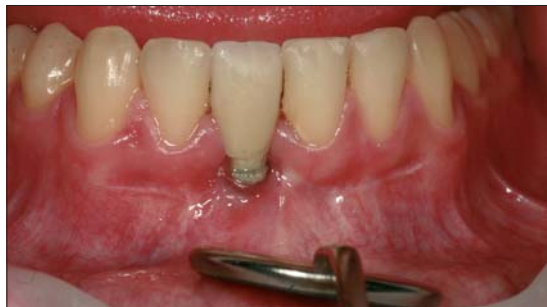Soft-tissue grafting is performed for different reasons:

1. Changing of the natural gingival biotype by augmentation → a preventive approach.
2. Root coverage → a curative approach in ready installed disease.

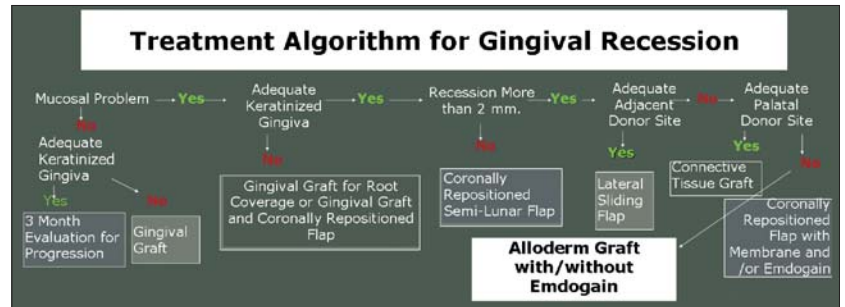
→ [page 22](#)



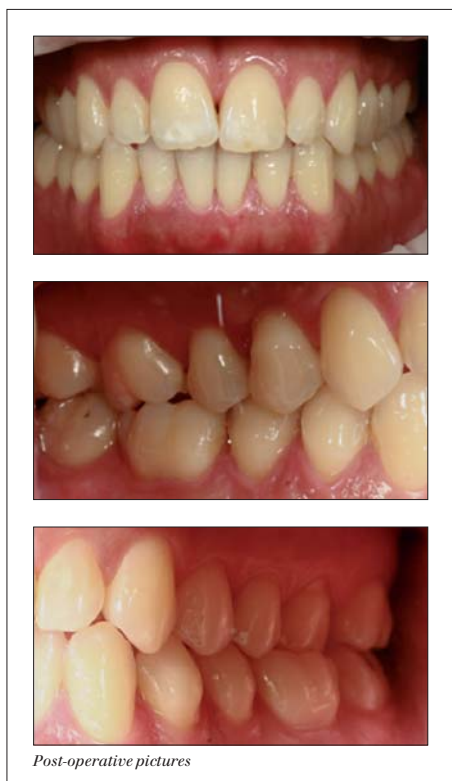Clinical picture showing a 'dark margin' of a PFM crown in a thin gingiva biotype patient having multiple recessions.



Clinical picture demonstrating gingival recession around an implant.




Picture demonstrating the 'Treatment Algorithm for Gingival Recession' (modification of the UCLA approach).



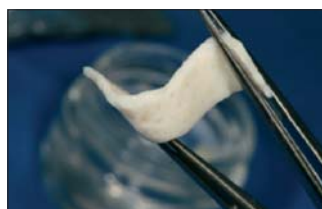Post-operative pictures



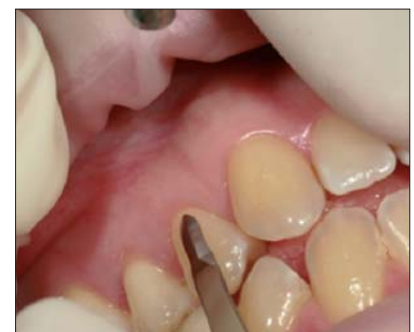Alloderme package



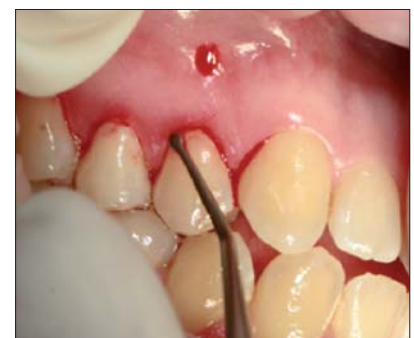... placed in sterile saline bath, for rehydration



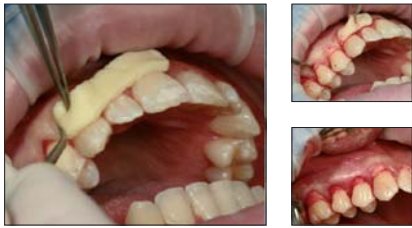... rehydrated and cut in strip



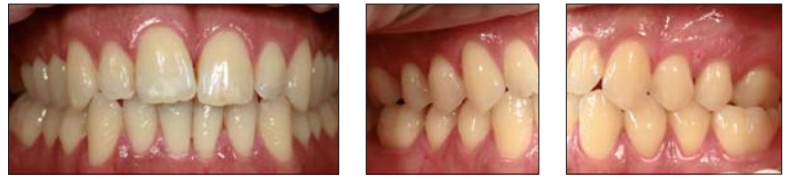Swann Morton surgical blade used for the cervical incision



Tunnel periosteum used to raise the flap



Placing the Alloderm under the raised tunnel flap



Postoperative pictures

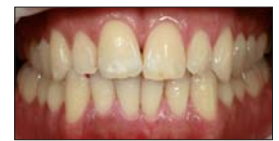← **PT** page 21

The Algorithm on page 21 should best exemplify diag-

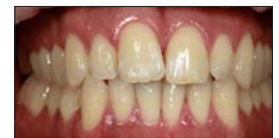nosis and adequate treatment.

Alloderm

Alloderm is an acellular dermal matrix derived from donated human skin. The donor material is deprived of the epidermis and immunogenic cells. It undergoes a final freeze drying and an extensive panel of serology tests and a sterilisation process.



Pre-operative pictures



Post-operative pictures

One can say that the Allograft Tissue is transformed into a Regenerative Tissue Matrix consisting of a complex acellular heterogenous scaffold, containing growth factors binding sites and blood vessel architecture.

It has been demonstrated that due to retained vascular channels the patients blood infiltration is facilitated and accelerated – revascularisation can start as early as one week after implantation.

Clinical case

A 29-year-old male was referred for the management and prevention of recession. The medical history was uncomplicated with no special recording in the dental history.

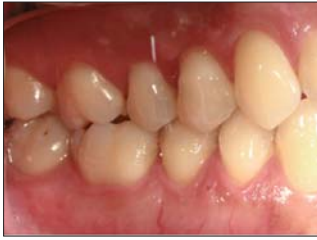The clinical dental examination proved:

- Thin gingiva biotype
- Temperature sensitivity
- Gingival recessions with tendency to expansion
- There were no signs of inflammation or ulceration.

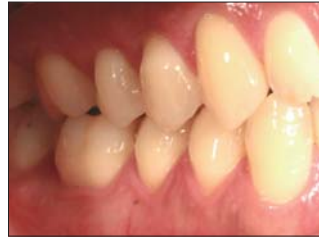The initial management was conservative and consisted in cleaning and hygiene instruction. Follow-up a few weeks later showed a clear improvement in oral hygiene. The patient was explained treatment goals and different available treatment options.

The selected and agreed treatment plan was two-fold:

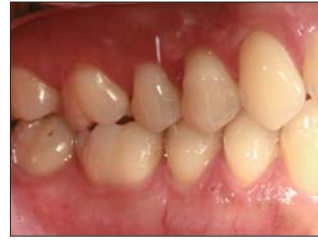- First to thicken the gingiva using graft technique (Alloderm)
- At a later stage for complete root coverage a 'coronally repositioned flap'. Consent was obtained.



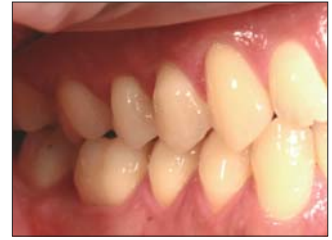Pre-op mirror view of the left side



Post-op view of the same side



Pre-op mirror view of the right side



Post-op mirror view of the same side

Step-by-step treatment

Preparing Alloderm for use: The package is opened and the graft is dropped into a sterile saline bath, where it is kept for 30 minutes. The paper back is removed from the graft. It is important to identify the two sides of the graft. The basement of the membrane is rough and does not absorb blood, while the dermal side does.

Preparation of the recipient side

Adequate anesthesia is administered – usually infiltration will suffice.

The surface of the root is scaled and planed. Papillary incisions are made using a Swann Morton blade to a depth of 3–4 mm apically. The papilla is left intact to prevent flap retraction and improve blood supply to the graft during the healing phase.

To lift the tunnelled papillae, a microsurgical papilla elevator is used and a mucoperiosteal pouch (past the mucogingival junction) is created.

The Alloderm graft is cut to fit from the distal of the canine to the mesial of the molar. The graft is inserted into the pouch preparation under the intact papilla using the micro papilla elevator. The graft is then positioned with the connective tissue side facing the bone.

The margins of the graft are fixed to the tooth with Histoacryl glue. No suture needed.

The patient was instructed not to brush the area for six weeks, to start rinsing the mouth with saline solution for seven days. After seven days, disinfection was performed with oral rinse with CHX solution. The patient was seen for postsurgical check up after two days, seven days and six weeks.

After six weeks, a thorough cleaning was performed and the patient instructed to restart regular hygiene. Healing was re-evaluated after three months and the next treatment step scheduled.

Conclusion

Early diagnosis and preventive regenerative periodontal treatment can avoid long-term gingival recession. Patients with a thin gingiva biotype will also lack adequate connective tissue in the palate for transplant. The use of donated human tissue represents a viable alternative technique. □

References are available on request.

EWOO